

Outcome of pregnancy in chromosomally normal fetuses with increased nuchal translucency in the first trimester

A. P. SOUKA, E. KRAMPL, S. BAKALIS, V. HEATH and K. H. NICOLAIDES

Harris Birthright Research Centre for Fetal Medicine, King's College Hospital, London, UK

KEYWORDS: 10–14-week scan, Cardiac defects, Fetal abnormalities, First trimester, Genetic syndromes, Nuchal translucency

ABSTRACT

Objectives To study the outcome of chromosomally normal pregnancies with increased nuchal translucency at the 10–14-week scan.

Design Retrospective study of 1320 chromosomally normal singleton pregnancies with nuchal translucency of ≥ 3.5 mm. In addition to fetal karyotyping these patients were managed with follow-up scans at 14–16 and 20–22 weeks, specialist fetal echocardiography and in selected cases by infection screening and further genetic testing.

Results In the 1320 pregnancies there were 68 (5.15%) spontaneous abortions or intrauterine deaths, 18 (1.36%) neonatal and infant deaths and 154 (11.67%) terminations of pregnancy. In the 1080 (81.82%) survivors, 60 (5.56%) had abnormalities requiring medical or surgical treatment or leading to mental handicap. The chance of a livebirth with no defects in the group with nuchal translucency of 3.5–4.4 mm was 86%, for those with translucency of 4.5–5.4 mm it was 77%, for those with translucency of 5.5–6.4 mm it was 67%, and for those with translucency of ≥ 6.5 mm it was 31%.

Conclusions Increased fetal nuchal translucency is associated with chromosomal abnormalities, many fetal defects and genetic syndromes. In the majority of cases a series of antenatal investigations, including fetal karyotyping, detailed scans, fetal echocardiography, as well as genetic testing and infection screening, that can be completed by 20 weeks of gestation would distinguish between the pregnancies destined to result in adverse outcome and those leading to the delivery of infants without major defects.

INTRODUCTION

The measurement of fetal nuchal translucency (NT) thickness at 10–14 weeks of gestation has been established as a sensitive, accurate and effective method of screening for chromosomal abnormalities¹. In addition, several studies have reported on

the association of increased NT with major cardiac defects², other structural defects and rare genetic syndromes³.

In a screening study involving 96 127 singleton pregnancies, the incidence of chromosomal defects increased with fetal NT thickness¹ (Table 1). A study of 693 chromosomally normal pregnancies with a fetal NT of at least 3.5 mm, which represents the 99th centile of the normal range, reported on the prevalence of adverse outcome, including major structural abnormalities and genetic syndromes³. This study is an expanded series of 1320 chromosomally normal fetuses with increased NT providing data on the prevalence of adverse outcome, which is examined in relation to both the measurement of fetal NT and the findings of the follow-up ultrasound scans.

METHODS

The Harris Birthright Research Centre for Fetal Medicine is a tertiary referral center. Patients found to have increased NT at the routine first-trimester scan in their local hospitals are referred for a detailed first-trimester anomaly scan, counseling and invasive tests for fetal karyotyping. The first-trimester scan includes measurement of the crown–rump length and NT as previously described⁴ and ultrasound examination of the following structures: skull, brain, chest, abdominal wall, stomach, bladder and upper and lower extremities. In pregnancies with increased NT and normal karyotype we recommend follow-up scans at 16 and 20 weeks of gestation and

Table 1 Incidence of chromosomal defects according to fetal nuchal translucency in a screening study involving 96 127 singleton pregnancies (Snijders *et al.* 1998¹)

Nuchal translucency (mm)	Total n	Chromosomal defects (n (%))
≤ 3.4	95 086	315 (0.33)
3.5–4.4	568	120 (21.12)
4.5–5.4	207	69 (33.33)
5.5–6.4	97	49 (50.51)
≥ 6.5	166	107 (64.45)

Correspondence: Prof K.H. Nicolaides, Harris Birthright Research Centre for Fetal Medicine, King's College Hospital, Denmark Hill, London SE5 9RS, UK (e-mail: fmf@fetalmedicine.com)

Received 12-2-01, Revised 19-3-01, Accepted 10-4-01

Table 2 Outcome of 1320 chromosomally normal pregnancies with increased nuchal translucency

NT (mm)	Total n	Termination of pregnancy (n (%))	Spontaneous fetal loss (n (%))	Postnatal death (n (%))	Live birth with abnormalities (n (%))	Live birth with no defects (n (%))
3.5–4.4	854	53 (6.2)	26 (3.0)	8 (0.9)	33 (3.9)	734 (85.9)
4.5–5.4	229	22 (9.6)	10 (4.4)	6 (2.6)	14 (6.1)	177 (77.3)
5.5–6.4	99	20 (20.2)	9 (9.1)	1 (1.0)	3 (3.0)	66 (66.7)
≥ 6.5	138	59 (42.8)	23 (16.7)	3 (2.2)	10 (7.3)	43 (31.2)
Total	1320	*154 (11.7)	68 (5.2)	18 (1.4)	60 (4.5)	1020 (77.3)

*In 102 (66%) of the 154 cases the termination was carried out after the diagnosis of fetal defects. NT, nuchal translucency.

from 1998 these patients have also had specialist fetal echocardiography. The follow-up scans are performed at the Harris Birthright Centre in the majority of cases. However, some women opt to have follow up at their local hospitals.

Demographic details and ultrasound findings were entered into a computer database at the time of scanning. Karyotype results and details of pregnancy outcome were entered as soon as they became available. Pregnancy outcome was obtained from the maternity units, the general practitioners or the patients themselves. Details on follow-up ultrasound scans were obtained from the Harris Birthright database or the obstetric ultrasound units if the follow-up scans were carried out locally.

A computer search was carried out to identify all singleton pregnancies with live fetuses and crown–rump length of 38–84 mm, NT of ≥ 3.5 mm, normal karyotype (or birth of a child with no features suggestive of chromosomal abnormality), estimated date of delivery before 1 July 2000 and known pregnancy outcome.

The prevalence of adverse pregnancy outcome (including miscarriage, intrauterine death, postnatal death or survival with mental handicap or defects requiring medical or surgical treatment) was calculated according to the NT measurement from the first-trimester scan. Minor structural defects, such as mild hydronephrosis, choroid plexus cysts, digital anomalies and cardiac defects not requiring treatment were not included in the calculations.

A review of the literature was carried out to determine the reported defects in chromosomally normal fetuses with increased NT thickness at 10–14-weeks of gestation. In addition, a search was made for studies reporting the diagnosis of fetal abnormalities at the 10–14-week scan and these studies were examined to identify the conditions that were associated with increased NT thickness.

Table 3 Miscarriages and intrauterine deaths by gestation and nuchal translucency measurement

NT (mm)	Total n	Gestational age at fetal loss (weeks)			
		≤ 15	16–20	21–25	26–30
3.5–4.4	26	14 ^{a,b}	8 ^c	2 ^{d,e}	2
4.5–5.4	10	7 ^{a,f,g}	2 ^{a,g}	1	0
5.5–6.4	9	7 ^{f,g} (×2)	1 ^g	1 ^g	0
> 6.5	23	15 ^f (×3), ^g (×2), ^h	6 ^{f,i,k}	1 ^k	1
Total	68	43	17	5	3

NT, nuchal translucency; ^aobstructive uropathy; ^bparvovirus infection; ^cspina bifida; ^dfetal growth restriction; ^ediaphragmatic hernia; ^fcardiac defect; ^ghydrops; ^hexomphalos; ⁱholoprosencephaly; ^kventriculomegaly.

RESULTS

The computer search identified 1320 chromosomally normal singleton pregnancies with NT ≥ 3.5 mm at a median gestation of 12 weeks (range, 10–14 weeks). The data of the first 693 fetuses that were previously reported by Souka *et al.*³ are included in the present study.

The outcome of the 1320 pregnancies is summarized in Table 2. There were 68 (5.15%) spontaneous abortions or intrauterine deaths (Table 3), 18 (1.36%) neonatal and infant deaths (Table 4) and 154 (11.67%) terminations of pregnancy. The indications for termination of pregnancy were prenatal diagnosis of fetal abnormalities ($n = 102$), progressive fetal hydrops ($n = 15$) and parental request ($n = 37$). Of the 1080 (81.82%) survivors, 60 (5.56%) had abnormalities requiring medical or surgical treatment or leading to mental handicap. In total there were 200 (15.15%) cases with abnormalities and the condition was diagnosed prenatally in 162 (80.50%) cases (Table 5).

From the study group of 1320 pregnancies, 1137 had follow-up scans at 15 and/or 20 weeks of gestation; in the remaining 183 cases there was pregnancy termination or miscarriage before 15 weeks in 128 cases and between 15 and 20 weeks in 55 cases. In the group of the 1137 cases that were available for follow up, ultrasound examination demonstrated fetal defects in 75 cases, persistent nuchal edema in 82

Table 4 Individual cases of neonatal and infant death and nuchal translucency measurement at the 10–14-week scan

NT (mm)	Diagnosis
3.5	Fetal akinesia deformation sequence
3.5	Growth restriction
3.6	Unexplained infant death
3.7	Pulmonary hypoplasia due to amniorrhaxis
4.0	Left isomerism
4.0	Gastroschisis
4.1	Congenital mesangial nephrotic syndrome
4.2	Dyserythropoietic anemia
4.5	Transposition of the great arteries
4.5	Growth restriction
4.6	Exomphalos
4.7	Diaphragmatic hernia
5.1	Diaphragmatic hernia
5.1	Diaphragmatic hernia
5.1	Congenital Finnish nephrosis
5.6	Spinal muscular atrophy
6.7	Fetal akinesia deformation sequence
7.1	Unexplained infant death
10.0	Unexplained infant death

cases (including six cases with generalized edema, ascites and/or pericardial effusion) and in 980 cases the sonographic examination was unremarkable (Table 6). In 16 of the 75 cases with structural defects, persistent nuchal edema was also present.

In the group of 82 pregnancies with apparently isolated and persistent nuchal edema, 15 (18.29%) cases had an adverse outcome (Table 7). In the group of 980 pregnancies without abnormal findings at the follow-up scans, there were 22

Table 5 Fetal abnormalities and genetic syndromes diagnosed prenatally, postnatally or by postmortem examination in chromosomally normal fetuses with increased nuchal translucency

Abnormality	Total n	Prenatal diagnosis (n)	Nuchal translucency (mm)				TOP (n)	IUD (n)	PND (n)	LB (n)
			3.5–4.4	4.5–5.4	5.5–6.4	> 6.4				
Anencephaly	3	3	2	1 ^p			3			
Encephalocele	2	2				2	2			
Ventriculomegaly	3	3	2 ^b			1 ^k	3			
Dandy–Walker malformation	4	4	2 ^{a,g}			2	4			
Holoprosencephaly	2	2		1		1	2			
Craniosynostosis	1			1					1	
Facial cleft	1	1			1 ⁱ				1	
Cystic hygroma	2	2			2		2			
Neck lipoma	1					1			1	
Cardiac defect	58	44	22	12	6	18 ^{m,q}	29	6	2	21
Diaphragmatic hernia	6	6	1 ⁿ	3	2		2	1	3	
CAM of the lungs	1	1				1				1
Exomphalos	11	11	4 ^{f,h}	1	2 ^{h,i}	4 ^{h,n}	7	2	1	1
Gastroschisis	1		1					1		
Bowel obstruction	3	1	1	2						3
Duodenal atresia	1		1							1
Crohn's disease	1		1							1
Hydronephrosis	5	5	5							5
Multicystic dysplastic kidneys	2	2	2 ^c				1			1
Infantile polycystic kidneys	2	2	1 ^d			1	2			
Renal agenesis	6	6	4 ^c	2 ^c			1			5
Congenital nephrotic syndrome	2	1	1 [*]		1 [*]				2	
Obstructive uropathy	11	11	4	3	3	1	8	3		
Cloacal exstrophy	1	1		1			1			
Hypospadias	2		2							2
Ambiguous genitalia	1			1						1
Spina bifida	3	3	2			1	2	1		
Talipes	5	3	4			1	1			4
Kyphoscoliosis	2	1		1	1		1			1
Body stalk anomaly	15	15	3	5	1	6	15			
Congenital lymphedema	1		1 [*]							1
Limb reduction defect	2	2	1 ^e	1			2			
Sirenomelia	1	1	1				1			
Fetal akinesia deformation sequence	11	11	3		1	7	9		2	
Short rib polydactyly	1	1	1				1			
Thanatophoric dwarfism	1	1	1				1			
Osteogenesis imperfecta	2	2	2 [*]				2			
Jarcho–Levin syndrome	1	1		1			1			
Skeletal dysplasia	2	2	1			1	2			
Nance–Sweeney syndrome	1			1						1
Beckwith–Wiedemann syndrome	1	1	1							1
Meckel–Gruber syndrome	1	1	1				1			
Dyserythropoietic anemia	1	1	1						1	
Blackfan–Diamond anemia	1			1						1
Neonatal myoclonic encephalopathy	1			1						1
Smith–Lemli–Opitz syndrome	2	2		1	1		2			
Noonan syndrome	2	2				2				2
Treacher–Collins syndrome	1			1						1
Fryn syndrome	1	1				1	1			
Spinal muscular atrophy	1					1			1	
Deficiency of the immune system	1					1				1
Unspecified syndrome	2	2	1 ^o		1					2
Severe developmental delay	4	1	3 ^l			1 ^l				4
Total	200	162	83	41	22	54	107	15	13	65

TOP, termination of the pregnancy; IUD, intrauterine death (includes spontaneous miscarriages); PND, postnatal death (includes neonatal and infant death); LB, live birth; CAM, cystic adenomatoid malformation. Symbols a–q refer to one case in each group with additional abnormalities:

^aexomphalos and hydronephrosis; ^bhypoplastic left kidney; ^cin these cases the defect was unilateral; ^dmicrognathia, clinodactyly and hypospadias; ^efacial cleft; ^fkyphoscoliosis; ^gmicrognathia and coarctation of the aorta; ^hPentalogy of Cantrell; ⁱventricular septal defect, coarctation of the aorta and spina bifida; ^jhorseshoe kidney; ^khydrups; ^lmicrodeletion of chromosome 9; ^mDi George syndrome; ⁿcardiac defect; ^oradial aplasia, micrognathia and arachnoid cyst; ^pexomphalos and spina bifida; ^qbilateral severe hydronephrosis. *These cases have been presented as case reports.

Table 6 Adverse outcome in fetuses with no structural defects (with or without nuchal edema) at the 20-week scan classified according to nuchal translucency at the 10–14-week scan

NT (mm)	Total n	Alive at 20 weeks (n (%))	Adverse outcome	
			No nuchal edema (n (%))	Nuchal edema (n (%))
3.5–4.4	854	793 (92.9)	13 ^a /726 (1.8)	3 ^b /30 (10.0)
4.5–5.4	229	203 (88.6)	7/166 (4.2)	2 ^c /18 (11.1)
5.5–6.4	99	73 (73.7)	0/54	1/12 (8.3)
≥ 6.5	138	68 (49.3)	2/34 (5.9)	9 ^b /22 (40.9)
Total	1320	1137 (86.1)	22 ^a /980 (2.2)	15 ^d /82 (18.3)

Fetal cardiac defects that would have been detected by specialist echocardiography are included (^an = 5; ^bn = 1; ^cn = 2; ^dn = 4). NT, nuchal translucency.

(2.24%) cases of adverse outcome (Table 8). The prevalence of severe developmental delay was 1.22% (1/82) and 0.41% (4/980) in the groups of persistent nuchal edema and normal follow-up, respectively. Specialist fetal echocardiography was not offered to patients in the early part of the study and during this period nine detectable cardiac defects were not diagnosed prenatally. If these cardiac defects had been excluded from the analysis, the rate of unexpected adverse outcome would have been 14.10% and 1.74% in the groups with persistent nuchal edema and normal follow up, respectively.

The conditions that were identified by the literature search to be associated with increased NT are summarized in Table 9^{5–72}.

DISCUSSION

This study provides further evidence that in chromosomally normal fetuses the risk of miscarriage, intrauterine death, diagnosis of major structural defects leading to termination of pregnancy, postnatal death or survival with defects, increases with increasing NT (Table 2). Consequently, in counseling parents with pregnancies with increased NT, the chance of an adverse outcome, including chromosomal defects (Table 1), in the group with a NT of 3.5–4.4 mm is 32%, for those with

Table 7 Individual adverse outcomes in fetuses with persistent and apparently isolated nuchal edema according to nuchal translucency measurement at the 10–14-week scan

NT (mm)	Diagnosis
3.6	Coarctation of the aorta
4.0	Patent ductus arteriosus
4.2	Dyserythropoietic anemia
4.5	Transposition of the great arteries
4.7	Aortic stenosis, patent ductus arteriosus
5.6	Congenital Finnish nephrosis
7.8	Cleft palate
7.8	Noonan syndrome
7.9	Unexplained hydrops fetalis
7.9	Unexplained intrauterine death at 30 weeks
8.8	Neck lipoma
8.8	Unexplained intrauterine death at 22 weeks
9.0	Noonan syndrome
10.0	Pulmonary stenosis
10.0	Unexplained hydrops fetalis

NT, nuchal translucency.

a NT of 4.5–5.4 mm it is 49%, for those with a NT of 5.5–6.4 mm it is 67%, and for those with a NT of ≥ 6.5 mm it is 89% (Figure 1).

There is a wide range of conditions that have been reported in fetuses with increased NT (Tables 5 and 9). Although in some cases the defect may be purely coincidental, in other cases there may be a true association operating through one or more of the following mechanisms: cardiac dysfunction in association with abnormalities of the heart and great arteries; venous congestion in the head and neck in association with the constriction of the fetal body in amnion rupture sequence or superior mediastinal compression found in diaphragmatic hernia or the narrow chest in skeletal dysplasia; failure of lymphatic drainage due to abnormal or delayed development of the lymphatic system or impaired fetal movements in

Table 8 Individual adverse outcomes in fetuses with no abnormal findings at antenatal follow-up ultrasound scans according to nuchal translucency measurement at the 10–14-week scan

NT (mm)	Diagnosis
3.5	Atrioventricular septal defect, asplenia
3.6	Severe developmental delay
3.5	Unexplained intrauterine death at 28 weeks
3.5	Neonatal death after delivery at 27 weeks
3.8	Severe developmental delay
3.8	Vesico-ureteric reflux
3.8	Ventricular septal defect, ventriculomegaly
4.0	Ventricular septal defect
4.2	Atrioventricular septal defect
*4.2	Severe developmental delay, microdeletion of chromosome 9
4.2	Unexplained intrauterine death at 28 weeks
4.2	Lymphedema
4.3	Tetralogy of Fallot
4.5	Treacher–Collins syndrome
4.6	Craniosynostosis
4.7	Neonatal myoclonic encephalopathy
4.8	Blackfan–Diamond anemia
5.0	Nance–Sweeney syndrome
5.1	Ambiguous genitalia
5.3	Scoliosis
6.7	Congenital immune deficiency
6.7	Neonatal death due to spinal muscular atrophy

In all cases there was no nuchal edema at the 20-week scan.

*In this case prenatal karyotyping showed no obvious defect and the diagnosis of microdeletion of chromosome 9 was made by postnatal karyotyping because of the developmental delay. NT, nuchal translucency.

Table 9 Fetal abnormalities and genetic syndromes reported in association with increased nuchal translucency

Abnormality	Source
Central nervous system defect	
Anencephaly	Adekunle <i>et al.</i> 1999 ⁵ ; this study
Craniosynostosis	This study
Dandy–Walker malformation	Bilardo <i>et al.</i> 1998 ⁶ ; this study
Diastematomyelia	Souka <i>et al.</i> 1998 ³
Encephalocele	This study
Holoprosencephaly	Pandya <i>et al.</i> 1995 ⁷ ; Salvesen and Goble 1995 ⁸ ; this study
Hydroletharus syndrome	Ammala and Salonen 1995 ⁹
Joubert syndrome	Reynders <i>et al.</i> 1997 ¹⁰
Microcephaly	Souka <i>et al.</i> 1998 ³
Macrocephaly	Adekunle <i>et al.</i> 1999 ⁵
Spina bifida	Adekunle <i>et al.</i> 1999 ⁵ ; this study
Iniencephaly	Cha'ban <i>et al.</i> 1996 ¹¹
Trigonocephaly C	Souka <i>et al.</i> 1998 ³
Ventriculomegaly	Pandya <i>et al.</i> 1995 ⁷ ; this study
Facial defect	
Agnathia/micrognathia	Bilardo <i>et al.</i> 1998 ⁶ ; this study
Facial cleft	Ville <i>et al.</i> 1992 ¹² ; Nadel <i>et al.</i> 1993 ¹³ ; this study
Microphthalmia	Souka <i>et al.</i> 1998 ³
Treacher–Collins syndrome	This study
Nuchal defect	
Cystic hygroma	Shulman <i>et al.</i> 1994 ¹⁴ ; this study
Neck lipoma	This study
Cardiac defect	Bronshstein <i>et al.</i> 1990 ¹⁵ ; Gembruch <i>et al.</i> 1990 ¹⁶ ; Ville <i>et al.</i> 1992 ¹² ; Gembruch <i>et al.</i> 1993 ¹⁷ ; Nadel <i>et al.</i> 1993 ¹³ ; Achiron <i>et al.</i> 1994 ¹⁸ ; Pandya <i>et al.</i> 1995 ⁷ ; Salvesen and Goble 1995 ⁸ ; Cha'ban <i>et al.</i> 1996 ¹¹ ; Bilardo <i>et al.</i> 1998 ⁶ ; Fukada <i>et al.</i> 1998 ²¹ ; Hafner <i>et al.</i> 1998 ¹⁹ ; van Vugt <i>et al.</i> 1998 ²⁰ ; Adekunle <i>et al.</i> 1999 ⁵ ; Hyett <i>et al.</i> 1999 ² ; Schwarzler <i>et al.</i> 1999 ²³ ; Zosmer <i>et al.</i> 1999 ²² ; Chaoui <i>et al.</i> 2000 ²⁴ ; Maymon <i>et al.</i> 2000 ²⁵ ; Mavrides <i>et al.</i> 2001 ²⁷ ; Michailidis and Economides 2001 ²⁶ ; this study
*Di George syndrome	Lazanakis <i>et al.</i> 1998 ²⁸
Pulmonary defect	
Cystic adenomatoid malformation	This study
Diaphragmatic hernia	Nadel <i>et al.</i> 1993 ¹³ ; Sebire <i>et al.</i> 1997 ²⁹ ; Pandya <i>et al.</i> 1995 ⁷ ; van Vugt <i>et al.</i> 1998 ²⁰ ; this study
Fryn syndrome	Bulas <i>et al.</i> 1992 ³⁰ ; Hosli <i>et al.</i> 1997 ³¹ ; this study
Abdominal wall defect	
Cloacal exstrophy	This study
Exomphalos	Ville <i>et al.</i> 1992 ¹² ; Nadel <i>et al.</i> 1993 ¹³ ; Pandya <i>et al.</i> 1995 ⁷ ; Snijders <i>et al.</i> 1995 ³² ; Cha'ban <i>et al.</i> 1996 ¹¹ ; van Zalen-Sprock <i>et al.</i> 1997 ³³ ; Adekunle <i>et al.</i> 1999 ⁵ ; this study
Gastroschisis	This study
Gastrointestinal defect	
Crohn's disease	This study
Duodenal atresia	van Vugt <i>et al.</i> 1998 ²⁰ ; this study
Esophageal atresia	Bilardo <i>et al.</i> 1998 ⁶ ; Brown and Nicolaides 2000 ³⁴
Small bowel obstruction	This study
Genitourinary defect	
Ambiguous genitalia	This study
*Congenital nephrotic syndrome	This study
Hydronephrosis	This study
Hypospadias	This study
Infantile polycystic kidneys	This study
Meckel–Gruber syndrome	van Vugt <i>et al.</i> 1998 ²⁰ ; this study
Megacystis	van Zalen-Sprock <i>et al.</i> 1992 ³⁵ ; Johnson <i>et al.</i> 1993 ³⁶ ; Trauffer <i>et al.</i> 1994 ³⁷ ; Pandya <i>et al.</i> 1995 ⁷ ; Sebire <i>et al.</i> 1996 ³⁸ ; van Vugt <i>et al.</i> 1998 ²⁰ ; Favre <i>et al.</i> 1999 ³⁹ ; Maymon <i>et al.</i> 2000 ²⁵ ; this study
Multicystic dysplastic kidneys	van Zalen-Sprock <i>et al.</i> 1992 ³⁵ ; Ville <i>et al.</i> 1992 ¹² ; Pandya <i>et al.</i> 1995 ⁷ ; Cha'ban <i>et al.</i> 1996 ¹¹ ; Reynders <i>et al.</i> 1997 ¹⁰ ; van Vugt <i>et al.</i> 1998 ²⁰ ; this study
Renal agenesis	Pandya <i>et al.</i> 1995 ⁷ ; this study
Skeletal defect	
Achondrogenesis	Fisk <i>et al.</i> 1991 ⁴⁰ ; Hewitt 1993 ⁴¹ ; Soothill <i>et al.</i> 1993 ⁴² ; Meizner and Barnhard 1995 ⁴³
*Achondroplasia	Fukada <i>et al.</i> 1998 ²¹
Asphyxiating thoracic dystrophy	Ben Ami <i>et al.</i> 1997 ⁴⁴
Blomstrand osteochondrodysplasia	den Hollander <i>et al.</i> 1997 ⁴⁵
Campomelic dwarfism	Hafner <i>et al.</i> 1995 ⁴⁶
Jarcho–Levin syndrome	Eliyahu <i>et al.</i> 1997 ⁴⁷ ; this study
Kyphoscoliosis	This study
Limb reduction defect	Trauffer <i>et al.</i> 1994 ³⁷ ; this study

Table 9 Continued

Abnormality	Source
Nance–Sweeney syndrome	This study
*Osteogenesis imperfecta	Makrydimas <i>et al.</i> 2001 ⁴⁸ ; this study
Roberts syndrome	Petrikovsky <i>et al.</i> 1997 ⁴⁹
Short rib polydactyly	Hill and Leary 1998 ⁵⁰
Sirenomelia	Fukada <i>et al.</i> 1999 ⁵¹ ; this study
Talipes equinovarus	Adekunle <i>et al.</i> 1999 ³ ; this study
*Thanatophoric dwarfism	This study
VACTER association	Souka <i>et al.</i> 1998 ³
Fetal anemia	
Blackfan–Diamond anemia	This study
Dyserythropoietic anemia	This study
Fanconi anemia	Tercanli <i>et al.</i> 2001 ⁵² ; Petrikovsky <i>et al.</i> 1996 ⁵³ ; Smulian <i>et al.</i> 1998 ⁵⁴ ; Markenson <i>et al.</i> 2000 ⁵⁵
Parvovirus B19 infection	
* α -thalassemia	Lam <i>et al.</i> 1999 ⁵⁶
Neuromuscular defect	
Fetal akinesia deformation sequence	Ville <i>et al.</i> 1992 ¹² ; Nadel <i>et al.</i> 1993 ¹³ ; Pandya <i>et al.</i> 1995 ⁷ ; Hyett <i>et al.</i> 1997 ⁵⁷ ; this study
*Myotonic dystrophy	Bilardo <i>et al.</i> 1998 ⁶
*Spinal muscular atrophy	Rijhsinghani <i>et al.</i> 1997 ⁵⁸ ; Bilardo <i>et al.</i> 1998 ⁶ ; van Vugt <i>et al.</i> 1998 ²⁰ ; Stiller <i>et al.</i> 1999 ⁵⁹ ; this study
Metabolic defect	
Beckwith–Wiedemann syndrome	This study
*GM1 gangliosidosis	Bilardo <i>et al.</i> 1998 ⁶
*Long-chain 3-hydroxyacyl-coenzyme A dehydrogenase deficiency	Tercanli <i>et al.</i> 2000 ⁶⁰
*Mucopolysaccharidosis type VII	van Eyndhoven <i>et al.</i> 1998 ⁶¹
*Smith–Lemli–Opitz syndrome	Hobbins <i>et al.</i> 1994 ⁶² ; Pandya <i>et al.</i> 1995 ⁷ ; Hyett <i>et al.</i> 1995 ⁶³ ; Sharp <i>et al.</i> 1997 ⁶⁴ ; Maymon <i>et al.</i> 1999 ⁶⁵ ; this study
Vitamin D resistant rickets	Brady <i>et al.</i> 1998 ⁶⁶
*Zellweger syndrome	Bilardo <i>et al.</i> 1998 ⁶ ; de Graaf <i>et al.</i> 1999 ⁶⁷ ; Christiaens <i>et al.</i> 2000 ⁶⁸
Other defect	
Body stalk anomaly	Pandya <i>et al.</i> 1995 ⁷ ; Daskalakis <i>et al.</i> 1997 ⁶⁹ ; this study
Brachmann–de Lange syndrome	Sekimoto <i>et al.</i> 2000 ⁷⁰
Charge association	Pandya <i>et al.</i> 1995 ⁷
Deficiency of the immune system	This study
Congenital lymphedema	This study
EEC syndrome	Bilardo <i>et al.</i> 1998 ⁶
Neonatal myoclonic encephalopathy	This study
Noonan syndrome	van Zalen-Sprock <i>et al.</i> 1992 ³⁵ ; Johnson <i>et al.</i> 1993 ³⁶ ; Trauffer <i>et al.</i> 1994 ³⁷ ; Reynders <i>et al.</i> 1997 ¹⁰ ; Bilardo <i>et al.</i> 1998 ⁶ ; Adekunle <i>et al.</i> 1999 ⁵ ; Achiron <i>et al.</i> 2000 ⁷¹ ; this study
Perlman syndrome	van der Stege <i>et al.</i> 1998 ⁷²
Stickler syndrome	Pandya <i>et al.</i> 1995 ⁷
Unspecified syndrome	Ville <i>et al.</i> 1992 ¹² ; this study
Severe developmental delay	van Vugt 1998 ²⁰ ; Adekunle <i>et al.</i> 1999 ⁵ ; this study

*Conditions that are amenable to early prenatal diagnosis by chorionic villus sampling.

various neuromuscular disorders; altered composition of the subcutaneous connective tissue and fetal anemia or hypoproteinemia.

There is strong evidence on the association between increased NT and trisomy 21 as well as all other major chromosomal abnormalities (Table 1). Consequently, the first line of management of such pregnancies should be the offer of fetal karyotyping. In the chromosomally normal group the parents should be counseled that even if the NT is more than 6.5 mm there is a one in three chance that the pregnancy would result in a live birth with no major defects (Table 2). Nevertheless, the association between increased NT and a wide range of structural abnormalities and genetic syndromes (Table 9) constitutes an indication for detailed follow-up scans, including fetal echocardiography, and possibly further genetic testing (Figure 2). Specialist echocardiography and anomaly scanning can lead to the diagnosis of many fetal

abnormalities from as early as 12 weeks⁷³. Following chorionic villus sampling and exclusion of a chromosomal abnormality, a follow-up scan at 14–16 weeks would determine the evolution of the NT and diagnose or exclude many fetal defects.

Persistence of unexplained NT or evolution to hydrops fetalis raises the possibility of congenital infection or a genetic syndrome⁷⁴. In this study nuchal edema was considered to be present if in the midsagittal plane of the neck there was subcutaneous edema that produced a characteristic tremor on ballotment of the fetal head⁷⁴. As shown in Table 5, a significant number of genetic conditions, such as spinal muscular atrophy, are now amenable to prenatal diagnosis by DNA testing and it would therefore be possible to undertake such testing in the chorionic villus sample that has already been obtained for fetal karyotyping. The diagnosis of congenital infection can be investigated by maternal serum infection screening. Sebire *et al.* investigated the possibility of infection in 426

chromosomally normal pregnancies with increased fetal NT thickness at 10–14 weeks of gestation and 63 with ‘unexplained’ second- or third-trimester fetal nuchal edema or hydrops⁷⁵. Evidence of recent maternal infection was present in six (1.4%) of the 426 pregnancies with increased fetal NT but in all cases a healthy infant was born with no evidence of infection. In contrast, ‘unexplained’ second- or third-trimester fetal hydrops was associated with maternal infection in six (9.5%) of the pregnancies and in all cases there was evidence of fetal infection.

The series of investigations suggested above would have identified the majority of conditions associated with adverse outcome in fetuses with increased NT. In those cases with no

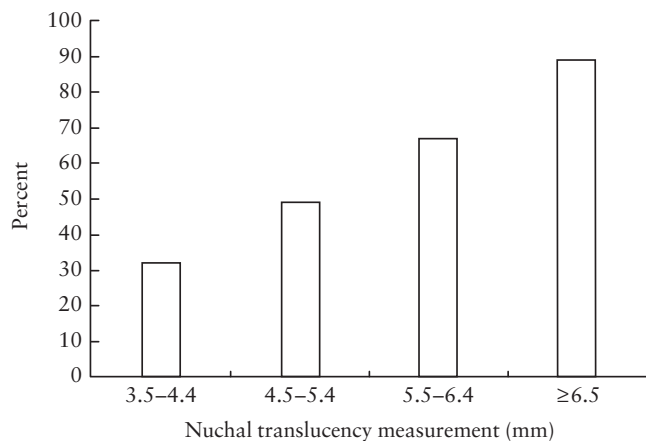


Figure 1 Incidence of adverse outcome in fetuses with increased nuchal translucency.

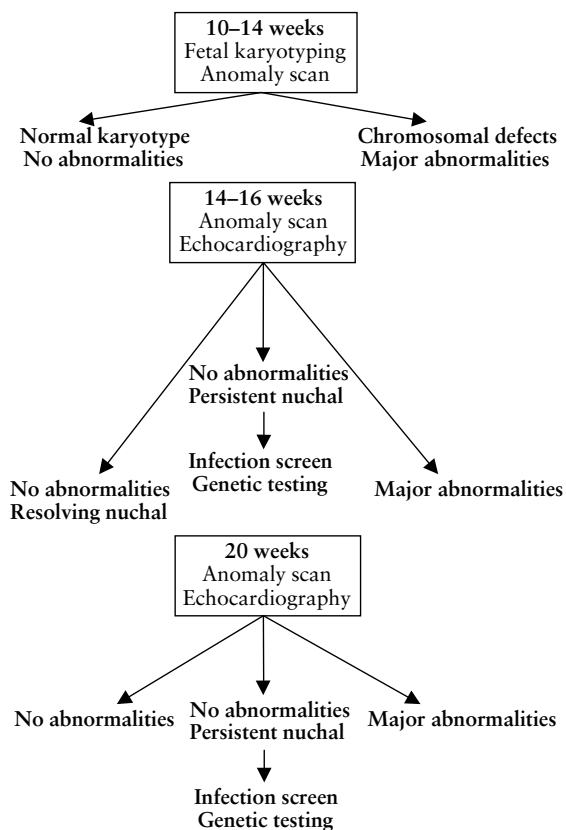


Figure 2 Management of pregnancies with increased fetal nuchal translucency

obvious abnormalities identified by 20 weeks of gestation, the parents can be counseled that the risk of an adverse outcome is very small. In the group of 980 pregnancies without abnormal findings at the follow-up scans, there were 22 (2.24%) cases of adverse outcome, including five with cardiac defects that are amenable to prenatal diagnosis by specialist fetal echocardiography (Tables 6 and 8). Although in patients with apparently unexplained nuchal edema at the 20-week scan, 18% had an adverse outcome, one third of these had potentially detectable cardiac defects, one third progressed to hydrops or resulted in unexplained intrauterine death and only one third resulted in live births with genetic syndromes, such as Noonan syndrome or Finnish nephrosis (Tables 6 and 7). In our study the prevalence of neurodevelopmental delay in the group with normal follow-up scans was 0.4% and in those with persistent nuchal edema it was 1.2%. In two previous studies of 63 and 38 pregnancies with increased NT, the prevalence of neurodevelopmental delay was 3.2% and 5.6%, respectively,^{5,20}. However, we acknowledge that the true prevalence of neurodevelopmental delay is likely to be underestimated because many such cases may not become apparent until several years after birth.

Increased fetal NT is associated with chromosomal abnormalities, many fetal defects and genetic syndromes. In the majority of cases the proposed series of antenatal investigations can help distinguish between the pregnancies destined to result in adverse outcome and those leading to the delivery of infants with no major defects.

ACKNOWLEDGMENT

This study was supported by The Fetal Medicine Foundation (Charity no. 1037116).

REFERENCES

- 1 Snijders RJM, Noble P, Sebire N, Souka A, Nicolaides KH. UK multicentre project on assessment of risk of trisomy 21 by maternal age and fetal nuchal translucency thickness at 10–14 weeks of gestation. *Lancet* 1998; 351: 343–6
- 2 Hyett JA, Perdu M, Sharland GK, Snijders RJM, Nicolaides KH. Using fetal nuchal translucency to screen for major congenital cardiac defects at 10–14 weeks of gestation: population based cohort study. *BMJ* 1999; 318: 81–5
- 3 Souka AP, Snijders RJM, Novakov A, Soares W, Nicolaides KH. Defects and syndromes in chromosomally normal fetuses with increased nuchal translucency at 10–14 weeks of gestation. *Ultrasound Obstet Gynecol* 1998; 11: 391–400
- 4 Nicolaides KH, Azar G, Byrne D, Mansur C, Marks K. Fetal nuchal translucency: ultrasound screening for chromosomal defects in the first trimester of pregnancy. *BMJ* 1992; 304: 867–89
- 5 Adekunle O, Gopee A, El-Sayed M, Thilaganathan B. Increased first-trimester nuchal translucency: pregnancy and infant outcomes after routine screening for Down’s syndrome in an unselected antenatal population. *Br J Radiol* 1999; 72: 457–60
- 6 Bilardo CM, Pajkrt E, de Graaf IM, Mol BWJ, Bleker OP. Outcome of fetuses with enlarged nuchal translucency and normal karyotype. *Ultrasound Obstet Gynecol* 1998; 11: 401–6
- 7 Pandya PP, Kondylis A, Hilbert L, Snijders RJM, Nicolaides KH. Chromosomal defects and outcome in 1015 fetuses with increased nuchal translucency. *Ultrasound Obstet Gynecol* 1995; 5: 15–9
- 8 Salvesen DR, Goble O. Early amniocentesis and fetal nuchal translucency in women requesting karyotyping for advanced maternal age. *Prenat Diagn* 1995; 15: 971–4

- 9 Ammala P, Salonen R. First-trimester diagnosis of hydrolethalus syndrome. *Ultrasound Obstet Gynecol* 1995; 5: 60–2
- 10 Reynders CS, Pauker SP, Benacerraf BR. First trimester isolated fetal nuchal lucency: significance and outcome. *J Ultrasound Med* 1997; 16: 101–5
- 11 Cha'ban FK, van Splunder P, Los FJ, Wladimiroff JW. Fetal outcome in nuchal translucency with emphasis on normal fetal karyotype. *Prenat Diagn* 1996; 16: 537–41
- 12 Ville Y, Lalondrelle C, Doumerc S, Daffos F, Frydman R, Oury JF, Dumez Y. First-trimester diagnosis of nuchal anomalies: significance and fetal outcome. *Ultrasound Obstet Gynecol* 1992; 2: 314–6
- 13 Nadel A, Bromley B, Benacerraf BR. Nuchal thickening or cystic hygromas in first- and early second-trimester fetuses: prognosis and outcome. *Obstet Gynecol* 1993; 82: 43–8
- 14 Shulman LP, Emerson DS, Grevengood C, Felker RE, Gross SJ, Phillips OP, Elias S. Clinical course and outcome of fetuses with isolated cystic nuchal lesions and normal karyotypes detected in the first trimester. *Am J Obstet Gynecol* 1994; 171: 1278–81
- 15 Bronshtein M, Siegler E, Yoffe N, Zimmer EZ. Prenatal diagnosis of ventricular septal defect and overriding aorta at 14 weeks' gestation, using transvaginal sonography. *Prenat Diagn* 1990; 10: 697–702
- 16 Gembruch U, Knopfle G, Chatterjee M, Bald R, Hansmann M. First-trimester diagnosis of fetal congenital heart disease by transvaginal two-dimensional and Doppler echocardiography. *Obstet Gynecol* 1990; 75: 496–8
- 17 Gembruch U, Knopfle G, Bald R, Hansmann M. Early diagnosis of congenital heart disease by transvaginal sonography. *Ultrasound Obstet Gynecol* 1993; 3: 310–7
- 18 Achiron R, Rotstein Z, Lipitz S, Mashiach S, Hegesh J. First-trimester diagnosis of fetal congenital heart disease by transvaginal sonography. *Obstet Gynecol* 1994; 84: 69–72
- 19 Hafner E, Schuchter K, Liebhart E, Philipp K. Results of routine fetal nuchal translucency measurements at 10–13 weeks in 4233 unselected pregnant women. *Prenat Diagn* 1998; 18: 29–34
- 20 van Vugt JMG, Tinnemans TWS, van Zalen-Sprock RM. Outcome and early childhood follow-up of chromosomally normal fetuses with increased nuchal translucency at 10–14 weeks' gestation. *Ultrasound Obstet Gynecol* 1998; 11: 407–9
- 21 Fukada Y, Yasumizu T, Takizawa M, Amemiya A, Hoshi K. The prognosis of fetuses with transient nuchal translucency in the first and early second trimester. *Acta Obstet Gynecol Scand* 1998; 76: 913–6
- 22 Zosmer N, Souter VL, Chan CSY, Huggon IC, Nicolaides KH. Early diagnosis of major cardiac defects in chromosomally normal fetuses with increased nuchal translucency. *Br J Obstet Gynaecol* 1999; 106: 829–33
- 23 Schwarzler P, Carvalho JS, Senat MV, Masroor T, Campbell S, Ville Y. Screening for fetal aneuploidies and fetal cardiac abnormalities by nuchal translucency thickness measurement at 10–14 weeks of gestation as part of routine antenatal care in an unselected population. *Br J Obstet Gynaecol* 1999; 106: 1029–34
- 24 Chaoui R, Machlitt A, Tennstedt C. Prenatal diagnosis of ventrico-coronary fistula in a late first trimester fetus presenting with increased nuchal translucency. *Ultrasound Obstet Gynecol* 2000; 15: 160–2
- 25 Maymon R, Jauniaux E, Cohen O, Dreazen E, Weinraub Z, Herman A. Pregnancy outcome and infant follow-up of fetuses with abnormally increased first trimester nuchal translucency. *Hum Reprod* 2000; 15: 2023–7
- 26 Michailidis GD, Economides DL. Nuchal translucency measurement and pregnancy outcome in karyotypically normal fetuses. *Ultrasound Obstet Gynecol* 2001; 17: 102–5
- 27 Mavrides E, Cobian-Sanchez F, Tekay A, Moscoso G, Campbell S, Thilaganathan B, Carvalho JS. Limitations of using first-trimester nuchal translucency measurement in routine screening for major congenital heart defects. *Ultrasound Obstet Gynecol* 2001; 17: 106–10
- 28 Lazanakis MS, Rodgers K, Economides DL. Increased nuchal translucency and CATCH 22. *Prenat Diagn* 1998; 18: 507–10
- 29 Sebire NJ, Snijders RJM, Davenport M, Greenough A, Nicolaides KH. Fetal nuchal translucency thickness at 10–14 weeks of gestation and congenital diaphragmatic hernia. *Obstet Gynecol* 1997; 90: 943–7
- 30 Bulas D, Saal H, Allen JF, Kapur S, Nies BM, Newman K. Cystic hygroma and congenital diaphragmatic hernia: early prenatal sonographic evaluation of Fryn's syndrome. *Prenat Diagn* 1992; 12: 867–75
- 31 Hosli IM, Tercanli S, Rehder H, Holzgreve W. Cystic hygroma as an early first-trimester ultrasound marker for recurrent Fryn's syndrome. *Ultrasound Obstet Gynecol* 1997; 10: 422–4
- 32 Snijders RJM, Sebire NJ, Souka A, Santiago C, Nicolaides KH. Fetal exomphalos and chromosomal defects: relationship to maternal age and gestation. *Ultrasound Obstet Gynecol* 1995; 6: 250–5
- 33 van Zalen-Sprock RM, van Vugt JMG, van Geijn HP. First-trimester sonography of physiological midgut herniation and early diagnosis of omphalocele. *Prenat Diagn* 1997; 17: 511–8
- 34 Brown RN, Nicolaides KH. Increased fetal nuchal translucency: possible association with esophageal atresia. *Ultrasound Obstet Gynecol* 2000; 15: 531–2
- 35 van Zalen-Sprock MM, van Vugt JMG, van Geijn HP. First-trimester diagnosis of cystic hygroma — course and outcome. *Am J Obstet Gynecol* 1992; 167: 94–8
- 36 Johnson MP, Johnson A, Holzgreve W, Isada NB, Wapner RJ, Treadwell MC, Heeger S, Evans M. First-trimester simple cystic hygroma: cause and outcome. *Am J Obstet Gynecol* 1993; 168: 156–61
- 37 Trauffer ML, Anderson CE, Johnson A, Heeger S, Morgan P, Wapner RJ. The natural history of euploid pregnancies with first-trimester cystic hygromas. *Am J Obstet Gynecol* 1994; 170: 1279–84
- 38 Sebire NJ, von Kaisenberg C, Rubio C, Snijders RJM, Nicolaides KH. Fetal megacystis at 10–14 weeks of gestation. *Ultrasound Obstet Gynecol* 1996; 8: 387–90
- 39 Favre R, Kohler B, GasSeries B, Muller F, Nisand I. Early fetal megacystis between 11 and 15 weeks of gestation. *Ultrasound Obstet Gynecol* 1999; 14: 402–6
- 40 Fisk NM, Vaughan J, Smidt M, Wigglesworth J. Transvaginal ultrasound recognition of nuchal oedema in the first-trimester diagnosis of achondrogenesis. *J Clin Ultrasound* 1991; 19: 586–90
- 41 Hewitt B. Nuchal translucency in the first trimester. *Aust NZ J Obstet Gynecol* 1993; 33: 389–91
- 42 Soothill PW, Vuthiwong C, Rees H. Achondrogenesis type 2 diagnosed by transvaginal ultrasound at 12 weeks of gestation. *Prenat Diagn* 1993; 13: 523–8
- 43 Meizner I, Barnhard Y. Achondrogenesis type I diagnosed by transvaginal ultrasonography at 13 weeks of gestation. *Am J Obstet Gynecol* 1995; 173: 1620–2
- 44 Ben Ami M, Perlitz Y, Haddad S, Matilsky M. Increased nuchal translucency is associated with asphyxiating thoracic dysplasia. *Ultrasound Obstet Gynecol* 1997; 10: 297–8
- 45 den Hollander NS, van der Harten HJ, Vermeij-Keers C, Niermeijer MF, Wladimiroff JW. First trimester diagnosis of Blomstrand lethal osteochondrodysplasia. *Am J Med Genet* 1997; 73: 345–50
- 46 Hafner E, Schuchter K, Philipp K. Screening for chromosomal abnormalities in an unselected population by fetal nuchal translucency. *Ultrasound Obstet Gynecol* 1995; 6: 330–3
- 47 Eliyahu S, Weiner E, Lahav D, Shalev E. Early sonographic diagnosis of Jarcho-Levin syndrome: a prospective screening program in one family. *Ultrasound Obstet Gynecol* 1997; 9: 314–8
- 48 Makrydimas G, Souka A, Skentou H, Lolis D, Nicolaides KH. Osteogenesis imperfecta and other skeletal dysplasias presenting with increased nuchal translucency in the first trimester. *Am J Med Genet* 2001; 98: 117–20
- 49 Petrikovsky BM, Gross B, Bialer M, Solamanzadeh K, Simhae E. Prenatal diagnosis of pseudothalidomide syndrome in consecutive pregnancies of a consanguineous couple. *Ultrasound Obstet Gynecol* 1997; 10: 425–8
- 50 Hill LM, Leary J. Transvaginal sonographic diagnosis of short-rib polydactyly dysplasia at 13 weeks' gestation. *Prenat Diagn* 1998; 18: 1198–201

- 51 Fukada Y, Yasumizu T, Tsurugi Y, Ohta S, Hoshi K. Caudal regression syndrome detected in a fetus with increased nuchal translucency. *Acta Obstet Gynecol Scand* 1999; 78: 655–6
- 52 Tercanli S, Miny P, Siebert MS, Hosli I, Surbek DV, Holzgreve W. Fanconi anemia associated with increased nuchal translucency detected by first-trimester ultrasound. *Ultrasound Obstet Gynecol* 2001; 17: 160–2
- 53 Petrikovsky BM, Baker D, Schneider E. Fetal hydrops secondary to human parvovirus infection in early pregnancy. *Prenat Diagn* 1996; 16: 342–4
- 54 Smulian JC, Egan JF, Rodis JF. Fetal hydrops in the first trimester associated with maternal parvovirus infection. *J Clin Ultrasound* 1998; 26: 314–6
- 55 Markenson G, Correia LA, Cohn G, Bayer L, Kanaan C. Parvoviral infection associated with increased nuchal translucency: a case report. *J Perinatol* 2000; 20: 129–31
- 56 Lam YH, Tang MH, Lee CP, Tse HY. Nuchal translucency in fetuses affected by homozygous. α -thalassaemia-1 at 12–13 weeks of gestation. *Ultrasound Obstet Gynecol* 1999; 13: 238–40
- 57 Hyett J, Noble P, Sebire NJ, Snijders RJM, Nicolaides KH. Lethal congenital arthrogryposis presents with increased nuchal translucency at 10–14 weeks of gestation. *Ultrasound Obstet Gynecol* 1997; 9: 310–3
- 58 Rijhsinghani A, Yankowitz J, Howser D, Williamson R. Sonographic and maternal serum screening abnormalities in fetuses affected by spinal muscular atrophy. *Prenat Diagn* 1997; 17: 166–9
- 59 Stiller RJ, Lieberson D, Herzlinger R, Siddiqui D, Laifer SA, Whetham JCG. The association of increased fetal nuchal translucency and spinal muscular atrophy type I. *Prenat Diagn* 1999; 19: 587–9
- 60 Tercanli S, Uyanik G, Cagdas A, Holzgreve W. Increased nuchal translucency in a case of long-chain 3-hydroxyacyl-coenzyme A dehydrogenase deficiency. *Fetal Diagn Ther* 2000; 15: 322–5
- 61 van Eyndhoven HWF, Ter Brugge HG, van Essen AJ, Kleijer WJ. β -glucuronidase deficiency as cause of recurrent hydrops fetalis: the first early prenatal diagnosis by chorionic villus sampling. *Prenat Diagn* 1998; 18: 959–62
- 62 Hobbins JC, Jones OW, Gottesfeld S, Persutte W. Transvaginal sonography and transabdominal embryoscopy in the first-trimester diagnosis of Smith-Lemli–Opitz syndrome, type 2. *Am J Obstet Gynecol* 1994; 171: 546–9
- 63 Hyett JA, Clayton PT, Moscoso G, Nicolaides KH. Increased first trimester nuchal translucency as a prenatal manifestation of Smith-Lemli–Opitz syndrome. *Am J Med Genet* 1995; 58: 374–6
- 64 Sharp P, Haant E, Fletcher JM, Khong TY, Carey WF. First-trimester diagnosis of Smith-Lemli–Opitz syndrome. *Prenat Diagn* 1997; 17: 355–61
- 65 Maymon R, Ogle RF, Chitty LS. Smith-Lemli–Opitz syndrome presenting with persisting nuchal oedema and non-immune hydrops. *Prenat Diagn* 1999; 19: 105–7
- 66 Brady AF, Pandya PP, Yuksel B, Greenough A, Patton M, Nicolaides KH. Outcome of chromosomally normal livebirths with increased fetal nuchal translucency at 10–14 weeks' gestation. *J Med Genet* 1998; 35: 222–4
- 67 de Graaf IM, Pajkrt E, Keessen M, Leschot NJ, Bilardo CM. Enlarged nuchal translucency and low serum protein concentration as possible markers for Zellweger syndrome. *Ultrasound Obstet Gynecol* 1999; 13: 268–70
- 68 Christiaens GCML, de Pater JM, Stoutenbeek P, Drogtrorp A, Wanders RJA, Beemer FA. First trimester nuchal anomalies as a prenatal sign of Zellweger syndrome. *Prenat Diagn* 2000; 20: 520–1
- 69 Daskalakis G, Sebire NJ, Jurkovic D, Snijders RJM, Nicolaides KH. Body stalk anomaly at 10–14 weeks of gestation. *Ultrasound Obstet Gynecol* 1997; 10: 416–8
- 70 Sekimoto H, Osada H, Kimura H, Kamiyama M, Arai K, Sekiya S. Prenatal findings in Brachmann–de Lange syndrome. *Arch Gynecol Obstet* 2000; 263: 182–4
- 71 Achiron R, Heggesh J, Grisaru D, Goldman B, Lipitz S, Yagel S, Frydman M. Noonan syndrome: a cryptic condition in early gestation. *Am J Med Genet* 2000; 92: 159–65
- 72 van der Stege A, van Eyck J, Arabin B. Prenatal ultrasound observation in subsequent pregnancies with Perlman syndrome. *Ultrasound Obstet Gynecol* 1998; 11: 149–51
- 73 Souka AP, Nicolaides KH. Diagnosis of fetal abnormalities at the 10–14 week scan. *Ultrasound Obstet Gynecol* 1997; 10: 429–42
- 74 Nicolaides KH, Azar G, Snijders RJM, Gosden CM. Fetal nuchal oedema: associated malformations and chromosomal defects. *Fetal Diagn Ther* 1992; 7: 123–31
- 75 Sebire NJ, Bianco D, Snidjers RJM, Zuckerman M, Nicolaides KH. Increased fetal nuchal translucency thickness at 10–14 weeks: is screening for maternal-fetal infection necessary? *Br J Obstet Gynaecol* 1997; 104: 212–5